

# Mitochondria-Targeted Plastoquinone Derivatives as Tools to Interrupt Execution of the Aging Program. 4. Age-Related Eye Disease. SkQ1 Returns Vision to Blind Animals

V. V. Neroev<sup>1</sup>, M. M. Archipova<sup>1</sup>, L. E. Bakeeva<sup>2</sup>, A. Zh. Fursova<sup>3</sup>, E. N. Grigorian<sup>4</sup>,  
A. Yu. Grishanova<sup>3</sup>, E. N. Iomdina<sup>1</sup>, Zh. N. Ivashchenko<sup>1</sup>, L. A. Katargina<sup>1</sup>,  
I. P. Khoroshilova-Maslova<sup>1</sup>, O. V. Kilina<sup>2</sup>, N. G. Kolosova<sup>3</sup>, E. P. Kopenkin<sup>5</sup>, S. S. Korshunov<sup>2</sup>,  
N. A. Kovaleva<sup>4</sup>, Yu. P. Novikova<sup>4</sup>, P. P. Philippov<sup>2</sup>, D. I. Pilipenko<sup>2</sup>, O. V. Robustova<sup>1</sup>,  
V. B. Saprunova<sup>2</sup>, I. I. Senin<sup>2</sup>, M. V. Skulachev<sup>6</sup>, L. F. Sotnikova<sup>5</sup>, N. A. Stefanova<sup>3</sup>,  
N. K. Tikhomirova<sup>2</sup>, I. V. Tsapenko<sup>1</sup>, A. I. Shchipanova<sup>1</sup>, R. A. Zinovkin<sup>2</sup>, and V. P. Skulachev<sup>2,6,7\*</sup>

<sup>1</sup>Helmholtz Moscow Research Institute of Eye Diseases, ul. Sadovaya-Chernogryazskaya 14/19, 105062 Moscow, Russia

<sup>2</sup>Belozersky Institute of Physico-Chemical Biology, Lomonosov Moscow State University,  
119991 Moscow, Russia; fax: (495) 939-0338; E-mail: skulach@belozersky.msu.ru

<sup>3</sup>Institute of Cytology and Genetics, Siberian Branch, Russian Academy of Sciences,  
pr. Lavrentieva 10, 630090 Novosibirsk, Russia

<sup>4</sup>Kol'tsov Institute of Developmental Biology, Russian Academy of Sciences, ul. Vavilova 26, 119991 Moscow, Russia

<sup>5</sup>Skryabin Moscow State Academy of Veterinary Medicine and Biotechnology, ul. Skryabina 23, 109472 Moscow, Russia

<sup>6</sup>Mitoengineering Center, Lomonosov Moscow State University, 119991 Moscow, Russia

<sup>7</sup>Faculty of Bioengineering and Bioinformatics, Lomonosov Moscow State University, 119899 Moscow, Russia

Received December 29, 2007

Revision received August 15, 2008

**Abstract**—Mitochondria-targeted cationic plastoquinone derivative SkQ1 (10-(6'-plastoquinonyl) decyltriphenylphosphonium) has been investigated as a potential tool for treating a number of ROS-related ocular diseases. In OXYS rats suffering from a ROS-induced progeria, very small amounts of SkQ1 (50 nmol/kg per day) added to food were found to prevent development of age-induced cataract and retinopathies of the eye, lipid peroxidation and protein carbonylation in skeletal muscles, as well as a decrease in bone mineralization. Instillation of drops of 250 nM SkQ1 reversed cataract and retinopathies in 3-12-month-old (but not in 24-month-old) OXYS rats. In rabbits, experimental uveitis and glaucoma were induced by immunization with arrestin and injections of hydroxypropyl methyl cellulose to the eye anterior sector, respectively. Uveitis was found to be prevented or reversed by instillation of 250 nM SkQ1 drops (four drops per day). Development of glaucoma was retarded by drops of 5  $\mu$ M SkQ1 (one drop daily). SkQ1 was tested in veterinarian practice. A totally of 271 animals (dogs, cats, and horses) suffering from retinopathies, uveitis, conjunctivitis, and cornea diseases were treated with drops of 250 nM SkQ1. In 242 cases, positive therapeutic effect was obvious. Among animals suffering from retinopathies, 89 were blind. In 67 cases, vision returned after SkQ1 treatment. In *ex vivo* studies of cultivated posterior retina sector, it was found that 20 nM SkQ1 strongly decreased macrophagal transformation of the retinal pigmented epithelial cells, an effect which might explain some of the above SkQ1 activities. It is concluded that low concentrations of SkQ1 are promising in treating retinopathies, cataract, uveitis, glaucoma, and some other ocular diseases.

DOI: 10.1134/S0006297908120043

**Key words:** mitochondria, antioxidants, retinopathies, cataract, uveitis, glaucoma

**Abbreviations:** MDA, malondialdehyde; ROS, reactive oxygen species; RPE, retinal pigmented epithelium; SkQs, cationic derivatives of plastoquinone or methyl plastoquinone; SkQ1, 10-(6'-plastoquinonyl) decyltriphenylphosphonium.

\* To whom correspondence should be addressed.

As reported in the preceding papers [1-3], very small amounts of mitochondria-targeted plastoquinone derivatives (SkQs) show pronounced antioxidant effects on model membranes, isolated mitochondria, and cell cultures. In the latter case, strong antiapoptotic and anti-necrotic effects were observed in situations when cell

death was induced or mediated by reactive oxygen species (ROS) [1]. It was also found that several age-related pathologies (arrhythmia, heart and kidney infarctions, stroke, p53-controlled lymphomas, and certain other types of cancer) can be successfully treated by SkQs in animals [2, 3].

In this paper, we shall continue the latter approach when studying age-related, ROS-mediated ocular diseases. In fact, retina is a tissue of the the highest risk of the ROS-induced damage since (i) it contains high level of polyunsaturated fatty acids, a very good target for ROS, (ii) it is exposed to light producing such ROS as singlet oxygen, and (iii) oxygen concentration in retina is near-arterial, i.e. much higher than in the great majority of other tissues (in spite of the fact that retina is a tissue of highest respiratory activity) [4].

There are numerous indications of a crucial role of ROS in the main age-related ocular pathologies, i.e. retinopathies (maculodystrophy [5, 6], retinitis pigmentosa [7, 8], hereditary optic neuropathy [9]), as well as glaucoma [10, 11], cataract [12, 13], and autoimmune uveitis [14, 15]. Polyunsaturated fatty acids in mitochondrial cardiolipin are first of all attacked by mitochondria-produced ROS that are quenched by SkQs [1]. This is why the above-listed pathologies attracted our attention as a possible field of therapeutic application of SkQs. Here we shall describe certain results obtained when animals suffering from retinopathies, cataract, uveitis, glaucoma, and some other eye diseases were treated with SkQ.

## MATERIALS AND METHODS

**Studies with OXYS rats.** *Lipid peroxidation and protein carbonylation* in skeletal muscles of OXYS and Wistar rats were investigated as described in refs. [16] and [17], respectively.

*Mineralization of vertebra and bones of extremities* were measured with a LUNAR Expert-XL X-ray bone densitometer.

*Measurements of activity of cytochrome P450 isoforms.* Microsomes were isolated from OXYS rat livers perfused by solution of 1.15% KCl and 20 mM Tris-HCl, pH 7.4. The perfused liver was homogenized in solution of the same composition. Supernatant obtained after low-speed centrifugation of homogenate was centrifuged at 100,000g for 1 h. Sediment of microsomes was suspended in 0.1 M potassium phosphate, pH 7.4, supplemented with 20% glycerol.

Levels of the P450 isoforms CYP1A1, CYP1A2, CYP2B + CYP2C, and CYP2B1 were fluorometrically measured as a rate of formation of resorufin from 7-ethoxyresorufin, 7-methoxyresorufin, 7-benzoxoresorufin, and 7-penthoxyresorufin, respectively [18].

*Ophthalmoscopic studies of OXYS and Wistar rats* were carried out with a Betta ophthalmoscope, an Opton fun-

dus-camera, and a Shin-Nippon SL-45 slit lamp. Degree of cataract was estimated as follows: 1 arbitrary unit (a.u.), certain lens area of slightly decreased transparency; 2 a.u., certain area of strongly decreased transparency; 3 a.u., strong decrease in transparency of the whole lens cortex and/or nucleus.

As to retinopathy, also three major stages of retinal damage were distinguished, namely, 1 a.u., appearance of drusen and other pathological changes in the retinal pigmented epithelium (RPE) and a partial atrophy of a choroid capillary layer; 2 a.u., exudative detachment of RPE and of retinal neuroepithelium, further choroid capillary layer atrophy; 3 a.u., neovascularization and exudative-hemorrhagic detachment of RPE and neuroepithelium; scarring.

**Studies of experimental uveitis.** *Arrestin purification.* Bovine retinal outer segments were prepared from retinas following Wilden and Kuhn [19]. Arrestin was purified by specific binding of this protein to phosphorylated and photoactivated rhodopsin [20], followed by chromatographic separations on a DEAE-cellulose column and on a Mono Q column [21].

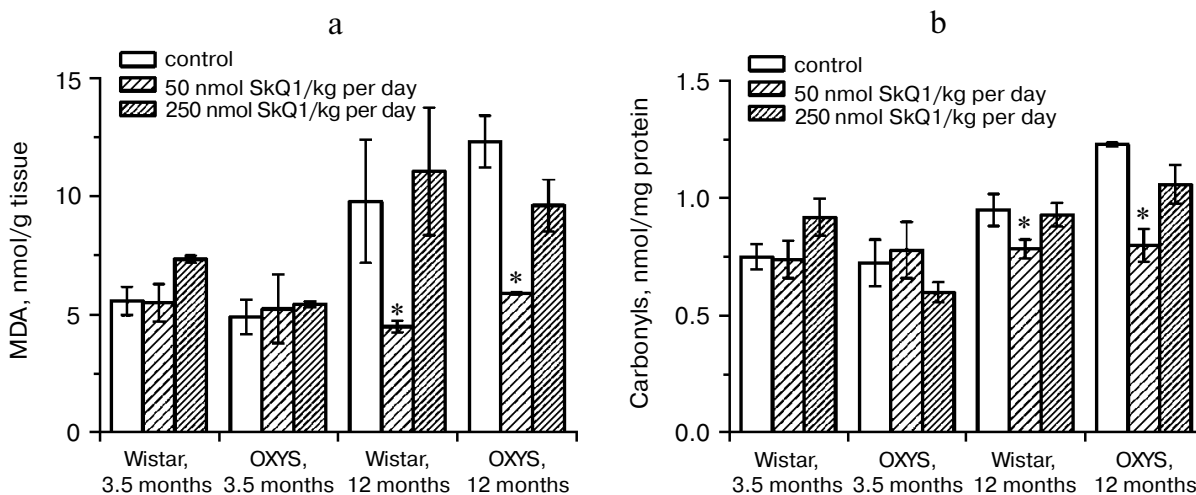
*Immunization of rabbits with arrestin.* Arrestin solution (1 ml in PBS, 0.8 mg/ml) was emulsified with equal volume of Freund's complete adjuvant (Sigma, USA) and inoculated into 6-month-old New Zealand white rabbits. The second inoculation was performed on day 30. Animals treated with Freund's adjuvant served as a control. After immunization, blood samples were taken from the rabbits and production of antibody was measured using an ELISA test.

*Measurement of nitrate level in the aqueous humor of anterior sector.* Nitric oxide was determined using a spectrophotometric assay based on the Griess reaction. Briefly, 100  $\mu$ l samples of the aqueous humor of the eye anterior sector were mixed with 1% sulfanilamide and 0.1% naphthyl ethylenediamine. After 10 min incubation at room temperature, we determined the concentration of nitrate in the mixture by measuring absorbance at 550 nm and comparing this value with absorbance of standard solutions of sodium nitrate.

*SkQ treatment.* SkQ1 was dissolved in a solution containing 10 mM potassium phosphate (pH 6.5) and 0.9% NaCl. Drops of the SkQ1 solution were instilled to one of rabbit's eyes (four times per day).

**Studies of experimental glaucoma.** Experimental glaucoma was induced by 10 injections (two injections per week) of 0.1 ml viscoelastic Celoftal (2% hydroxypropyl methyl cellulose) to anterior sector of the both eyes of a rabbit [22]. To the right eye, Vetomitin, a pharmaceutical form of SkQ1, was daily instilled whereas the left eye was used as a control to the SkQ1 treatment.

Among rabbits treated with SkQ1, four animals obtained drops containing 5  $\mu$ M SkQ1. Other four rabbits obtained 25  $\mu$ M SkQ1. Before the first Celoftal injection, the eyes were investigated to measure parameters of the



**Fig. 1.** Age-dependent increase in lipid peroxidation (a) and protein carbonylation (b) in skeletal muscles of OXYS and Wistar rats is abolished by adding to the food 50 nmol SkQ1/kg per day. Here and below: vertical bars, standard errors; \*, probability of insignificant difference between the SkQ1-treated and SkQ1-nontreated groups  $p < 0.05$ .

healthy animals. The following devices were used: a GlauTest-60 eye tonograph, an Angiodin-Ophthalmoscopy (Russia) ultrasonic ophthalmoscope, and a Cannon (Japan) fundus-camera.

**Cultivation of rat eye posterior sector.** Preparations of eye posterior sector were obtained from eyes of narcotized adult (2-3 months) Wistar rats (the treatment carried out according to bioethics regulations of the Russian Academy of Sciences). Procedures of obtaining, roller cultivation, fixation, as well as methods of investigation of the preparations are described in detail in [23]. Briefly, the eye anterior sector containing the cornea, iris, and lens was removed and two types of the remaining posterior sector were used for roller cultivation. In one case, the posterior eye sector before cultivation was incubated for 3-5 times in 5 ml commercial DMEM medium with phenol red, 3% L-glutamine, 4% gentamicin (medium A), and 10 mM EDTA. Afterward, neural retina was removed and the remaining part of the sector (i.e. RPE, choroid, and sclera) was used. In the other case, neural retina was not removed. In both cases, samples of the eye posterior sector were put into flasks containing medium A and 10% fetal calf serum with 20 nM SkQ1 or without SkQ1. Then the flasks were placed into a roller and cultivated in a dark sterile box at 60 rpm and 35.5°C for 7 or 14 days. The medium was not changed during the whole period of roller cultivation. After cultivation, the samples were fixed with 4% formaldehyde and Bouin's solution. Serial 7- $\mu$ m cross-sections (Reichert OME microtome) were stained with hematoxylin and eosin. To visualize macrophages, an anti-macrophage antibody (Sigma) was applied. Images obtained were scrutinized using an Olympus AH-3 microscope, a digital camera, and a computer with Lite, Corel Draw, Adobe Photoshop, Excel, and Plot Calc program packages.

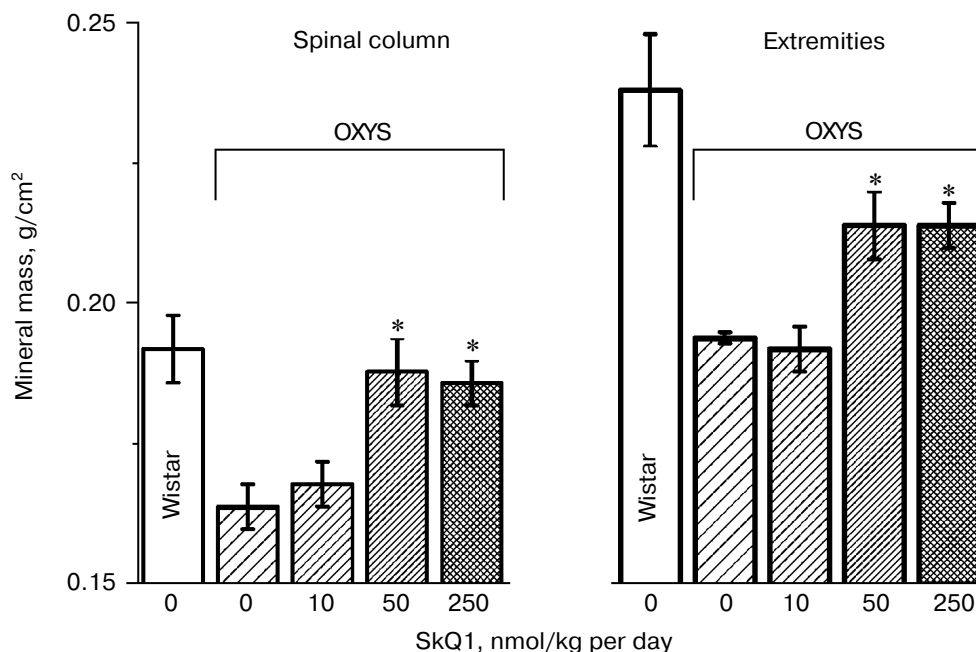
## RESULTS

**Prevention and reversal of age-dependent cataract and retinopathy in OXYS rats.** As a model for *in vivo* antioxidant effects of SkQs, we used OXYS rats, a strain suffering from constant oxidative stress [24]. In these rats, cataract and retinopathy were shown to appear as early as at three-month age [25-27].

In the first series of experiments, we investigated age-dependent consequences of oxidative stress in OXYS rats, trying to abrogate them by means of SkQ1 added to their food. It was found (Fig. 1, a and b) that levels of lipid peroxidation (estimated by measuring malondialdehyde (MDA)) and oxidation (carbonylation) of proteins are higher in skeletal muscles of one-year-old Wistar rats than in three-month-old ones. The effect of age was even larger in OXYS rats. Feeding with very small amount of SkQ1 (50 nmol/kg per day) resulted in a decrease in the lipid and protein oxidation levels. As to the mineral mass levels in vertebra and extremities, these parameters were lower in OXYS than in Wistar rats due to progeria-induced osteoporosis. Again, SkQ1 feeding proved to be favorable, increasing the mineral mass in OXYS rats (Fig. 2).

Thus, the presented data show that SkQ1 is competent in preventing some consequences of oxidative stress in OXYS rats. Then an attempt was made to treat by SkQ1 eye diseases in OXYS rats. As experiments showed, addition of the same SkQ1 amounts to the food completely prevented development of cataract and retinopathy in OXYS rats up to age of two years (Fig. 3 (see color insert) and Table 1; see also Supplementary information, Figs. S1 and S2<sup>1</sup>). Vitamin E added to the food was much less

<sup>1</sup> Supplementary Information is linked to the online version of the paper at <http://www.protein.bio.msu.ru/biokhimiya>.



**Fig. 2.** SkQ1 prevents development of osteoporosis in OXYS rats. Ordinate, mineral mass of corresponding bones. Age of rats, 9.5 months. SkQ1 was added to the food at age 1.5 months. \*  $p < 0.05$ .

effective than SkQ1 (Fig. 4). It is remarkable that the SkQ1 effects were not accompanied by any induction of cytochromes P450 in liver (Table 2), in contrast to those of vitamin E (not shown).

It was also found that instillations of drops of nanomolar SkQ1 significantly reverse pathological

changes in middle-age OXYS animals (Figs. 5 and 6). The latter effect was also observed in Wistar rats suffering from cataract (Figs. 5 and 6). In very old (more than 18 months) rats, neither cataract nor retinopathy was reversed by SkQ1 (not shown), although it still effectively prevented the diseases (Fig. 3, a-c, see color insert). The

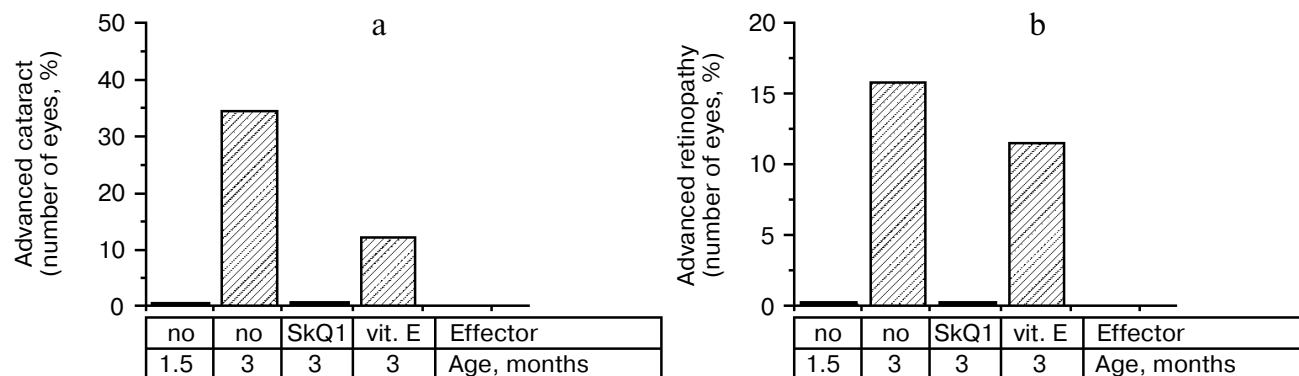
**Table 1.** Effect of SkQ1 added to food (250 nmol/kg per day) on the b-wave magnitude of the rat electroretinogram

Strain	OXYS			Wistar			
	Age (months)	3	24	24	3	24	24
SkQ1		-	-	+	-	-	+
b-Wave, $\mu\text{V}$		$56 \pm 3$	$19 \pm 13$	$42 \pm 9$	$54 \pm 11$	$37 \pm 9$	$55 \pm 12$

Note: Standard errors are indicated (each group contained 5-12 animals).

**Table 2.** SkQ1 feeding for 1.5 months does not affect levels of cytochrome P450 in liver microsomes of 14.5-month-old OXYS rats

SkQ1, nmol/kg per day	Activity of cytochrome P450 isoforms (pmol/min per mg protein)			
	CYP1A1	CYP1A2	CYP2B + CYP2C	CYP2B1
0	$299 \pm 44$	$323 \pm 25$	$366 \pm 55$	$311 \pm 120$
50	$228 \pm 27$	$314 \pm 37$	$311 \pm 45$	$244 \pm 55$
250	$325 \pm 22$	$324 \pm 32$	$314 \pm 53$	$187 \pm 51$



**Fig. 4.** Comparison of protective effects of SkQ1 (50 nmol/kg per day) and vitamin E (500  $\mu$ mol/kg per day) against cataract (a) and retinopathies (b) in OXYS rats.

above conclusion concerning preventive effect of SkQ1 on 24-month-old OXYS rats was confirmed by histological analysis of sections across the retina (Fig. 7; see color insert). The figure shows that in OXYS rats without SkQ1 the photoreceptor layer is absent, whereas OXYS rats receiving SkQ1 during all their life retained this layer. In old Wistar rats, the photoreceptor layer was present even without SkQ1. These results are in line with our observations that the electroretinogram disappeared in the majority of the 24-month-old OXYS rats but was retained in OXYS rats with SkQ1 as well as in Wistar rats (Fig. 3c and Table 1).

Reversal of an already developed retinopathy by SkQ1 drops was confirmed by electron microscopy data. As shown in Fig. 8 and Table 3, retinopathy in 11-month-old OXYS rats results in obliteration of choriocapillaries. This parameter is at least partially normalized after 1.5-month instillations of 250 nM SkQ1 (one drop daily). Reappearance of choriocapillaries in the presence of SkQ1 was accompanied with normalization of some other

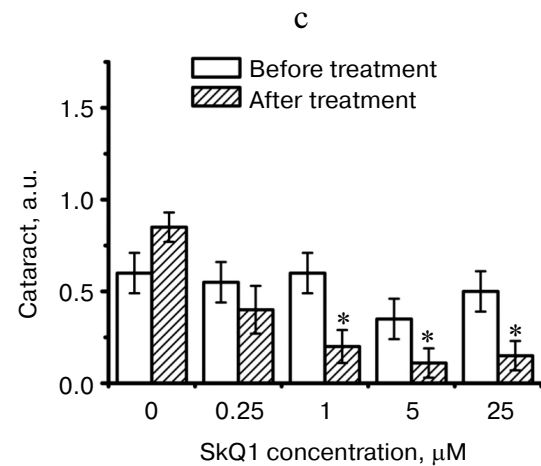
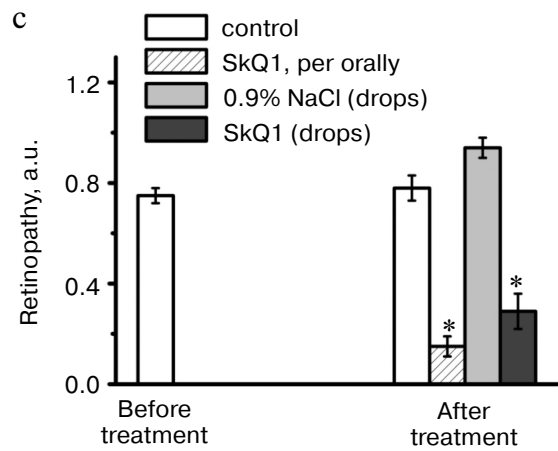
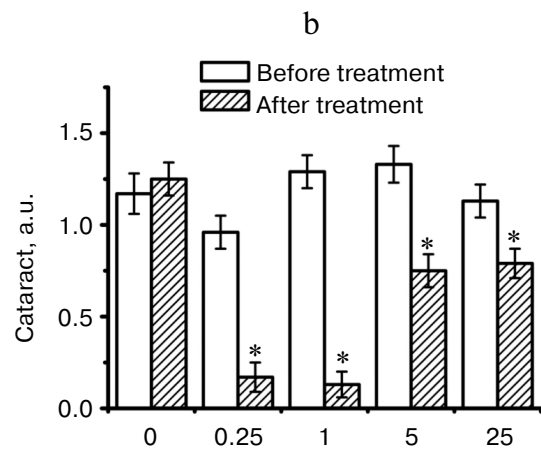
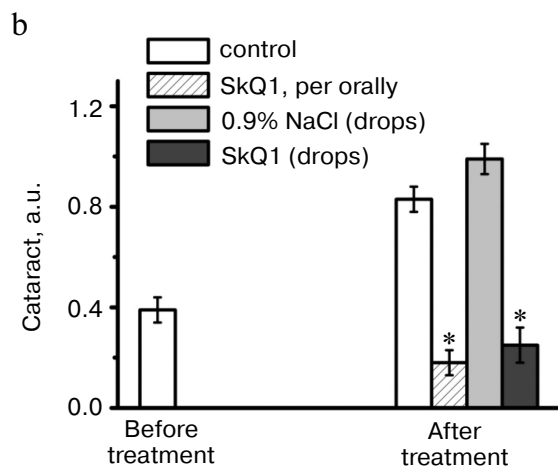
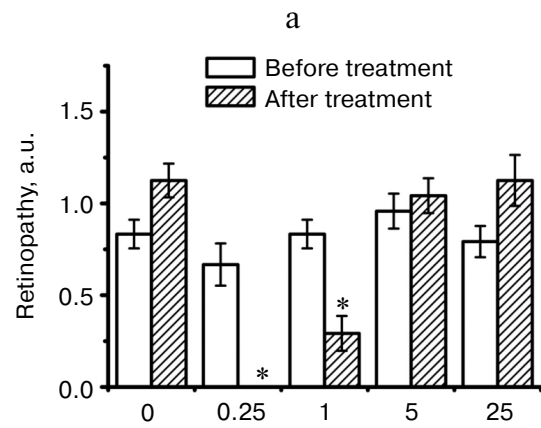
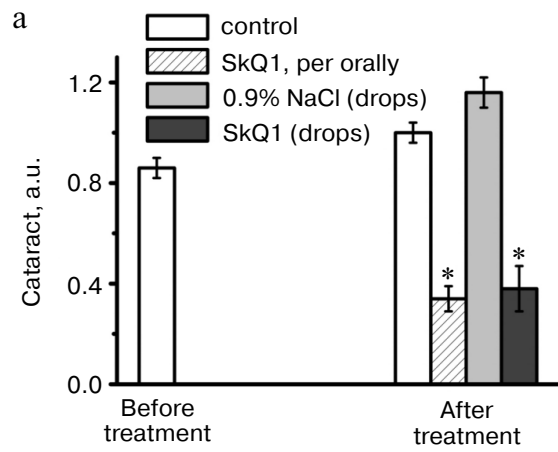
morphological features, i.e. distribution of lipofuscin granules in retinal pigment epithelial cells (Fig. S3, a and b) and disappearance of hernias formed due to disruption of Bruch's membrane (Fig. S3c).

Favorable effects of SkQ1 can disappear when it was added in excess. In skeletal muscles of OXYS rats, this occurred at 250 nmol SkQ1/kg per day (Fig. 1). In bones of the same rats, 250 nmol SkQ1 was still as effective as 50 nmol (Fig. 2). In eyes of OXYS rats, drops of 10 nM–1  $\mu$ M SkQ1 were effective in reversal of cataract and retinopathy, 5  $\mu$ M being ineffective. As to eyes of Wistar rats, even 25  $\mu$ M SkQ1 was still of favorable activity (Figs. 5 and 6). The above relationships can be explained assuming that (i) disappearance of therapeutic action of SkQ1 is due to prooxidant activity of its high concentrations [1] in OXYS rats suffering from constant oxidative stress.

**SkQ1 prevents and reverses blindness in experimental uveitis.** Uveitis has also been shown to be mediated by mitochondrial ROS [25], so we tried to use SkQ1 for treatment of this eye disease, too. To this end, a rabbit model

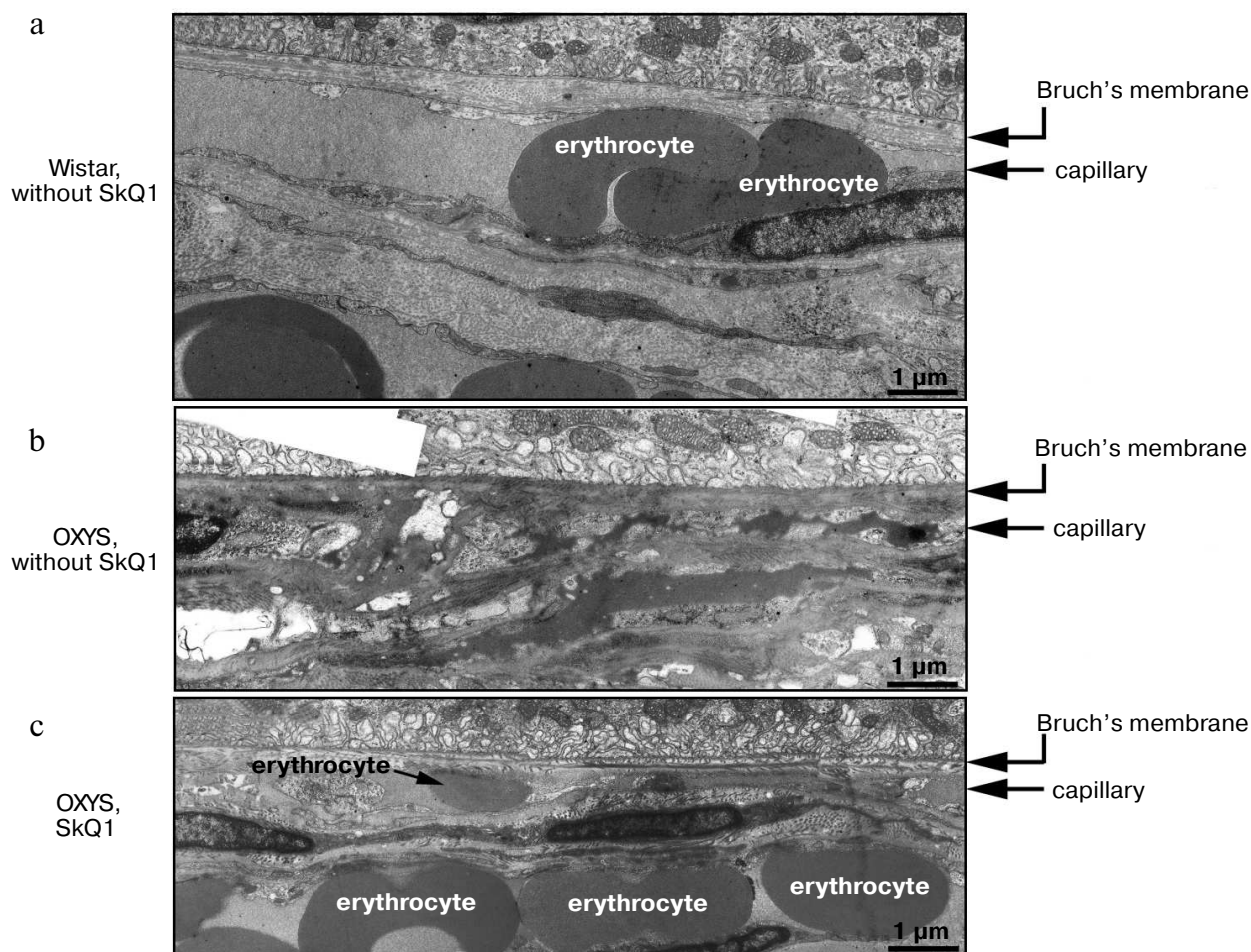
**Table 3.** State of choriocapillaries in retina of 11-month-old rats. Therapeutic effect of SkQ1 (one drop of 250 nM SkQ1 per day during the last 68 days)

Rat strain	SkQ1	Degree of retinopathy, a.u.		Number of capillaries along 450- $\mu$ m retina section		
		before SkQ1	after SkQ1	no obliteration	partial obliteration	complete obliteration
OXYS	–	2	–	0	3	8
OXYS	–	2	–	3	5	8
OXYS	–	2	–	4	3	4
OXYS	+	2	0	9	1	3
OXYS	+	2	0.5	7	2	1
OXYS	+	2	0	9	3	3
Wistar	–	0	–	15	0	0



**Fig. 5.** Instillations of the 250 nM SkQ1 drops or feeding of 50 nmol SkQ1/kg per day during 1.5 months reverse already developed cataract and retinopathies in OXYS (a, c) and Wistar (b) rats. Age before treatment, 9 months. \*  $p < 0.05$ .

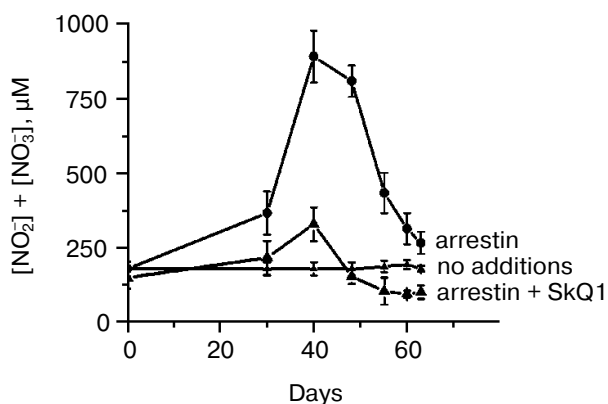
**Fig. 6.** Therapeutic effect of various SkQ1 concentrations upon already developed retinopathies and cataract in OXYS (a, b) and Wistar (c) rats. The treatment (one drop of SkQ1 solution daily) was started when rats were 9-month-old. Drops of SkQ1 were instilled during 52 days. In each group, 24 eyes of 12 animals (a, b) or 20 eyes of 10 animals (c) were studied. \*  $p < 0.05$ .



**Fig. 8.** Electron microscopic study of retina of 11-month-old Wistar (a) and OXYS (b, c) rats. c) Drops of 250 nM SkQ1 were instilled during the last 68 days.

of experimental uveitis was investigated. Experimental uveitis was induced by immunization of the animal by a photoreceptor-specific protein, arrestin, which resulted in blindness. This effect was prevented and reversed by SkQ1 instillations (four drops of 250 nM SkQ1 per day; not shown). It was also found (Fig. 9) that the same SkQ1 treatment strongly inhibited formation of  $\text{NO}_2^-$  and  $\text{NO}_3^-$  in eyes of the uveitis-suffering animals (under uveitis, these processes are known to be initiated by interaction of NO with  $\text{O}_2^{\cdot -}$  [28, 29]).

**SkQ1 prevents development of experimental glaucoma in rabbits.** In rabbits, experimental glaucoma was induced by a series of Celoftal instillations to the eye anterior sector. This resulted in appearance of such typical glaucoma features as an increase in intraocular pressure ( $P_0$ ), a strong decrease in the aqueous humor outflow ( $C$ ) as well as in humor production ( $F$ ), a strong rise of Bekker's coefficient ( $BC$ ), and some increase of the lens thickness (Table 4). Analysis of photographs obtained



**Fig. 9.** SkQ1 prevents experimental uveitis-induced increase in nitrite and nitrate levels in the aqueous humor of the eye anterior sector. Twenty eyes (10 rabbits) were studied, namely, six eyes without and 14 eyes with SkQ1 (four drops of 250 nM SkQ1 were instilled daily during 33 days).

**Table 4.** Drops of 5  $\mu\text{M}$  SkQ1 prevent development of experimental glaucoma in rabbits

Group/Parameter	$P_0$	$C$	$F$	$BC$	Lens thickness, mm
Normal	$17.4 \pm 0.7$	$0.16 \pm 0.02$	$1.28 \pm 0.26$	$108 \pm 24.2$	$7.3 \pm 0.08$
Glaucoma	$19.6 \pm 0.8^*$	$0.05 \pm 0.01^*$	$0.38 \pm 0.13^*$	$387 \pm 47.4^*$	$7.9 \pm 0.14^*$
Glaucoma + 5 $\mu\text{M}$ SkQ1	$16.5 \pm 0.8$	$0.14 \pm 0.04$	$2.5 \pm 0.49^*$	$117.2 \pm 27.6$	$7.5 \pm 0.08$
Glaucoma + 25 $\mu\text{M}$ SkQ1	$22.5 \pm 1.0^*$	$0.10 \pm 0.04$	$2.0 \pm 0.43$	$224.6 \pm 39.2^*$	$7.8 \pm 0.21^*$

\*  $p < 0.05$  for the eye with experimental glaucoma vs. normal eye.

**Table 5.** Therapeutic effect of instillations of Vetomitin (drops of 250 nM SkQ1) on retinopathies

Animal species	Number of animals					
	before treatment			after treatment		
	blind	partial loss of vision	total	vision is returned to blind animal	vision is improved	vision is not improved
Dog	58	19	77	46	19	12
Cat	27	9	36	17	5	14
Horse	4	18	22	4	18	0
Total	89	46	135	67	42	26

using a fundus camera revealed excavation of the optic disk (not shown). All these parameters were normalized if treatment with the glaucoma inducer was accompanied by instillation of drops of 5  $\mu\text{M}$  SkQ1 solution. Higher (25  $\mu\text{M}$ ) (Table 4) and lower (0.25  $\mu\text{M}$ ; not shown) SkQ1 concentrations proved to be less efficient than 5  $\mu\text{M}$  SkQ1.

**SkQ1 prevents macrophagal transformation of RPE and destruction of retina *ex vivo*.** A number of retinopathies are known to be accompanied with a ROS-mediated transformation of the retinal pigment epithelial (RPE) cells to macrophages that attack other retinal cells [29, 30]. If this process is arrested by SkQ1, this might explain, at least partially, the above described favorable effect of our compound upon certain retinopathies and uveitis.

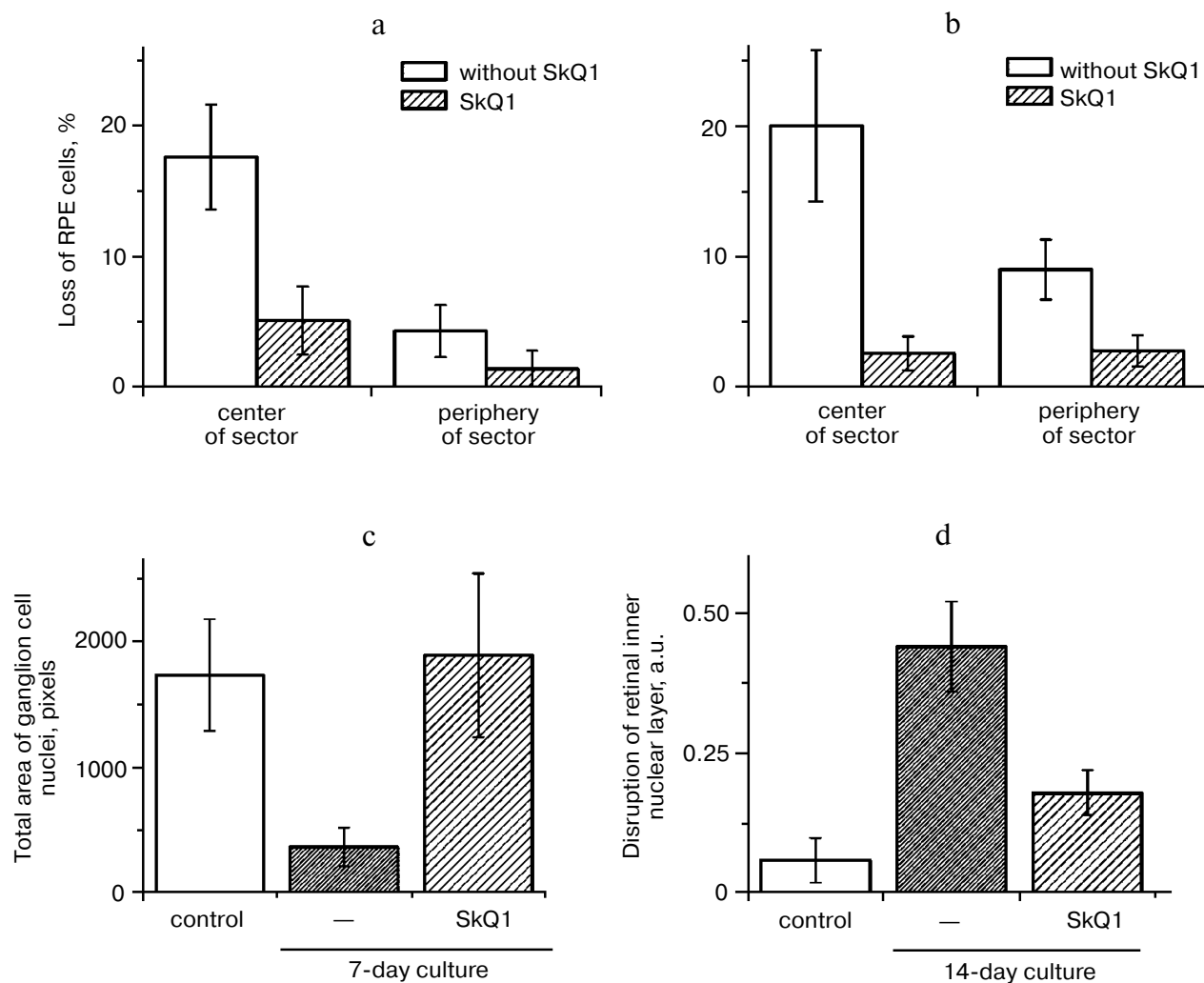
Macrophagal RPE cell transformation was studied in an *ex vivo* system, i.e. eye posterior sector obtained from two-month-old Wistar rats and cultivation in a sterile box for 7 (Fig. 10, a and c) or 14 (Fig. 10, b and d) days. As one can see in Fig. 10a, one week cultivation results in some loss of RPE cells, which was more pronounced in the center of the sector. Simultaneously, the number of macrophages was strongly increased (Fig. S4). Both these effects were strongly inhibited by 20 nM SkQ1 added to the cultivation medium. This action paralleled prevention

of disappearance of the ganglion cells (Fig. 10c) and of inner nuclear layer of the photoreceptor cells (Fig. 10d).

**Veterinary practice experiment of application of SkQ1 to treat various animal ocular pathologies.** Finally, SkQ1 was applied in veterinarian practice in cases when conventional medical treatments failed. A total of 135 animals (dogs, cats, and horses) suffering from various retinopathies were treated daily with drops of 250 nM SkQ1. In 89 cases, the animals were completely blind before the treatment. Vision was returned to 67 of them (Table 5). There was not a single case when SkQ1 had an unfavorable effect or its efficiency declined in the course of the treatment time.

Electroretinograms of a dog whose visual function was recovered by means of 250 nM SkQ1 instillations are shown in Fig. 11 (see color insert). The dog was blind because of inherited retinal dysplasia. As the figure shows, before the SkQ1 treatment there was practically no electric response to light. After 27 days of SkQ1 instillations, visual function was partially recovered and some electric response appeared. Even larger response was revealed on day 42 of the treatment, which was accompanied with further improvement of vision (for details, see Supplementary Information).





**Fig. 10.** Protective effect of 20 nM SkQ1 on the posterior sector of the rat eye during 7 (a, c) or 14 days (b, d) of roller cultivation. The center and peripheral regions of the sector were analyzed. a, b) After cultivation. c, d) White columns, before cultivation; black or striped columns, after cultivation without or with SkQ1, respectively.

Among dogs, cats, and horses suffering from retinopathies were those with inherited retinal dysplasia (degeneration), progressing retinal degeneration, or a secondary retinal degeneration. The best results of the SkQ1 treatment were obtained with inherited dysplasia (a positive effect in 67% cases) and secondary degeneration (in 54% cases). As to progressing degeneration, SkQ1 helped in 29% cases. Moreover, SkQ1 was effective in some cases of dry eye syndrome as well as for treatment of uveitis and some other autoimmune eye diseases, conjunctivitis, and certain corneal diseases (Table 6). SkQ1 drops were without effect on neuro-ophthalmological pathologies.

## DISCUSSION

As mentioned above, retina is a tissue where risk of ROS-induced damage is highest. The  $O_2$  concentration in

retina is almost as high as in lung, which increases probability of ROS formation. In addition, in contrast to lung, retina is illuminated by the light also initiating generation of ROS. Moreover, the amount of polyunsaturated lipids (which are targets for ROS) is much higher in retina than in lung and other tissues [4]. It is not surprising, therefore, that the most frequent ocular diseases are ROS-mediated [4-15].

Mitochondria are usually either the primary source of ROS [31, 32] or mediators of burst of ROS formation in other cellular compartments ("ROS-induced ROS release" [1, 33]). This is why it was reasonable to try mitochondria-targeted rechargeable antioxidant SkQ1 as a medicine to treat ocular diseases. OXYS rats suffering from constant oxidative stress proved to be a convenient model for such a study. Here it was found that small amounts of SkQ1, i.e. 50 nmol (or 0.03 mg)/kg per day, decreased levels of lipid peroxidation and protein car-

**Table 6.** Therapeutic effect of instillation of Vetomitin (drops of 250 nM SkQ1) on uveitis, conjunctivitis, and corneal diseases

Animal species	Total	Positive effect	No change
Uveitis			
Dog	26	23	3
Cat	8	8	0
Horse	19	19	0
Total	53	50	3
Conjunctivitis			
Dog	32	32	0
Cat	15	15	0
Horse	5	5	0
Total	52	52	0
Cornea diseases			
Dog	31	31	0

bonylation in skeletal muscles, and increased mineralization of bones of OXYS rats, which was decreased due to osteoporosis (Figs. 1 and 2). These data indicated that SkQ1 could mitigate oxidative stress and related progeria in OXYS rats.

Further experiments showed that the same amounts of SkQ1 prevented development of cataract and retinopathies, which appeared in the control (SkQ1 non-treated) OXYS rats as early as at 3rd month of life. With SkQ1 (50 nmol/kg per day), these age-induced diseases did not develop at least up to 2-years of age (Figs. 3 (a and b), 7, and S1 (a and b)). At this age, the majority of OXYS rats were practically blind, showing no light-induced electric response of the retina. The response was retained if animals were fed with SkQ1 (Fig. 3c and Table 1). Vitamin E proved to be much less efficient than SkQ1. Even 500  $\mu\text{mol}$  vitamin E/kg per day (i.e. 10,000-fold higher than SkQ1 dose) decreased the cataract and retinopathy levels far less strongly than SkQ1 (Fig. 4). Importantly, the SkQ1 amounts competent in successful treating ocular diseases were without effect upon the cytochrome P450 levels in liver endoplasmic reticulum (Table 2), in contrast to vitamin E which induced these cytochromes. Such a difference between SkQ1 and vitamin E could be explained by (i) much lower amount of SkQ1 used and (ii) the fact that mitochondria should win over other intracellular compartments (including endoplasmic reticulum where cytochrome P450 is localized) in competition for SkQ.

If a rat was not too old, daily instillations of one drop of extremely diluted (250 nM) SkQ1 solution were found to be of excellent therapeutic effect upon already devel-

oped cataract and retinopathies (Figs. 5, 6, and 8). In this case, the amount of SkQ1 added daily was as small as about 0.015  $\mu\text{g}/\text{kg}$  per day (cf. 0.03 mg/kg per day in the experiments where SkQ1 was received with the food).

Obliteration of choriocapillaries is a typical feature of retinopathy development in OXYS rats. In 11-month-old animals, this pathology was effectively reversed by SkQ1 drops as seen in electron micrographs shown in Fig. 8. It should be mentioned that an attempt to treat inherited retinopathies by a mitochondria-targeted antioxidant was recently undertaken by Wright and coworkers [34]. They used MitoQ and failed to obtain any positive result. The reason for this might be small size of the window between anti- and prooxidant concentrations of MitoQ [1].

Retinopathies in both OXYS rats and Wright's mice were a consequence of certain genetic injuries. We tried to use our compound to treat two experimentally induced eye pathologies, i.e. uveitis and glaucoma.

In rabbits, experimental uveitis was induced by immunization of the animals with the retinal protein arrestin, which resulted in blindness. Vision was returned by a 5-week course of instillations of four drops of 250 nM SkQ1 per day. Pretreatment with the SkQ1 drops prevented development of uveitis, which was seen not only in photographs of a fundus camera but also when the  $\text{NO}_2^- + \text{NO}_3^-$  level in the aqueous humor of eye anterior sector was measured (Fig. 9). The uveitis experiments were especially demonstrative since the SkQ1 drops were instilled into one eye only, whereas the other eye remained non-treated as a control. As a result, all the rabbits in the cages turned in a way allowing viewing by the treated eye of a person coming into the room.

Instillations of 5  $\mu\text{M}$  SkQ1 were very effective in preventing experimental glaucoma induced by injection of Celofal to the eye anterior sector of rabbits (Table 4). Like some other measured parameters, the efficiency of SkQ1 showed a concentration optimum. The efficiency lowered when SkQ1 concentration increased from 5 to 25  $\mu\text{M}$  or decreased to 0.25  $\mu\text{M}$ .

The medicine Vetomitin containing 250 nM SkQ1 was tested at the Department of Ophthalmology, K. I. Skryabin Russian Veterinarian Academy. Almost 300 dogs, cats, and horses suffering from retinopathies, uveitis, conjunctivitis, and cornea diseases were treated by instillations of Vetomitin drops. In more than 200 cases, obvious improvement was observed. Treatment of animals becoming blind due to retinopathies was demonstrative. Vision returned to 67 of 89 our animal patients (Table 5). For certain case descriptions, see Supplementary Information.

In an *ex vivo* study, the mechanism of SkQ1 effects was investigated. In these experiments, it was found that transformation of RPE cells to macrophages [29, 30] in cultivated eye posterior sector is strongly decreased by SkQ1 at concentration as low as 20 nM (Fig. 10). Such an inhibition of this ROS-linked process might at least partially explain the favorable effect of SkQ1 on retina in various ocular pathologies.

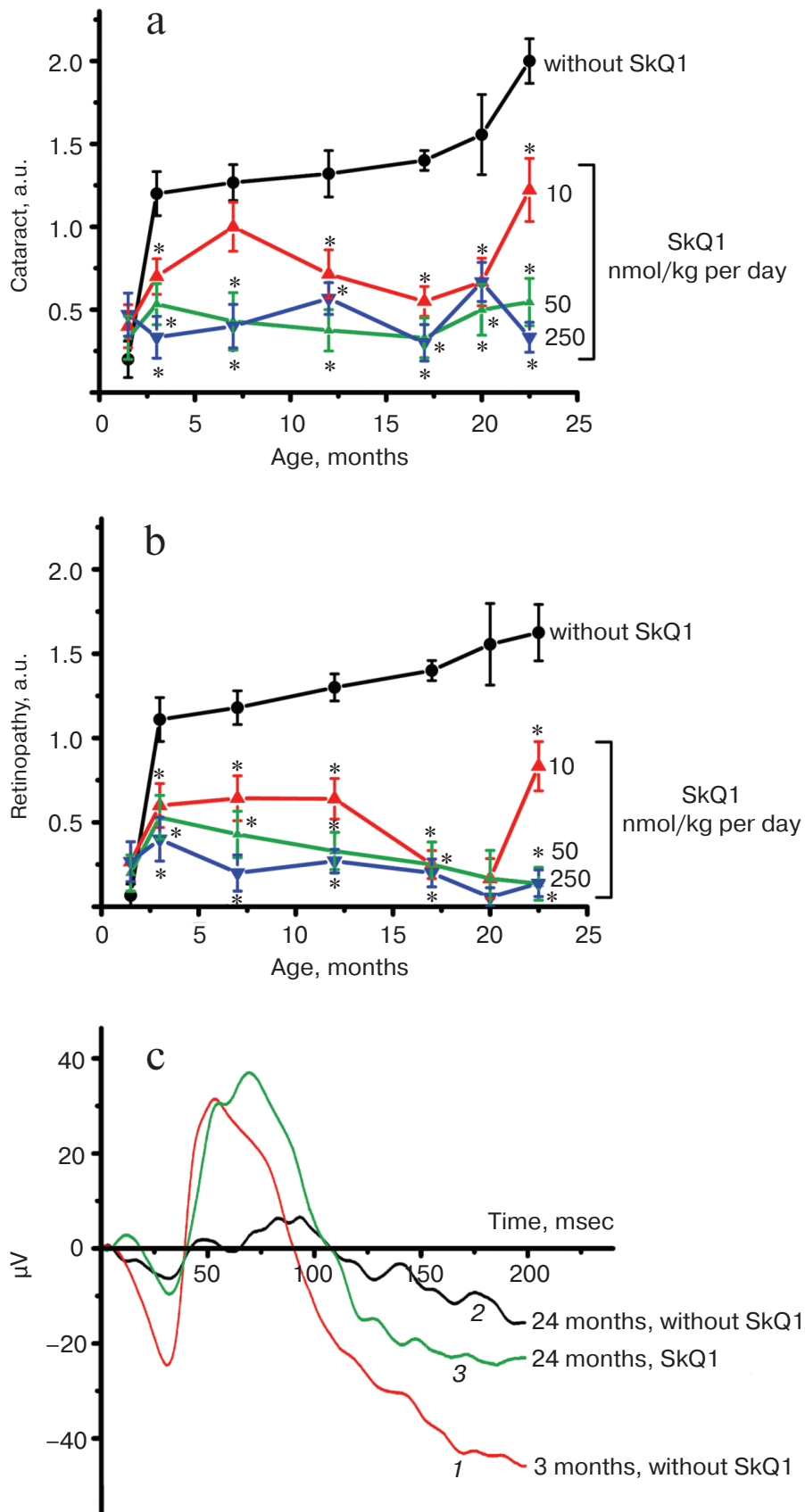
We are very grateful Professor V. A. Sadovnichii, Rector of Moscow State University, for his interest in the project and encouragement. We thank E. Yu. Zernyy and V. A. Churyumov for their participation in certain experiments. Generous support of Mr. O. V. Deripaska, which in fact made possible this study, is greatly appreciated.

Supported by Mitotechnology LLC, M. V. Lomonosov Moscow State University, the Vol'noe Delo Foundation (grant No. 99F-06), Russian Ministry of Education and Science (grant "Leading Scientific Schools" No. 5762.2008.4).

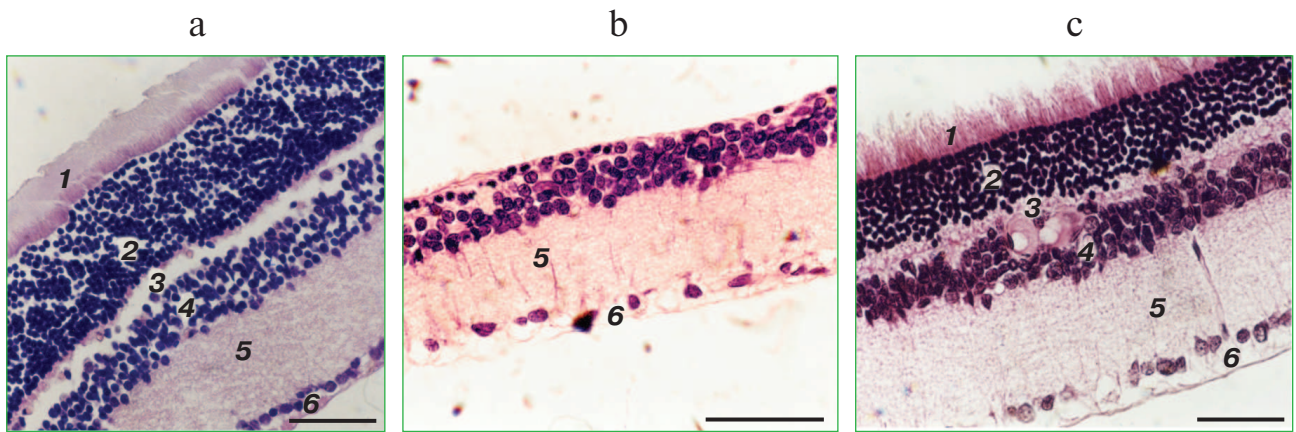
## REFERENCES

1. Antonenko, Y. N., Avetisyan, A. V., Bakeeva, L. E., Chernyak, B. V., Chertkov, V. A., Domnina, L. V., Ivanova, O. Yu., Izyumov, D. S., Khailova, L. S., Klishin, S. S., Korshunova, G. A., Lyamzaev, K. G., Muntyan, M. S., Nepryakhina, O. K., Pashkovskaya, A. A., Pletjushkina, O. Yu., Pustovidko, A. V., Roginsky, V. A., Rokitskaya, T. I., Ruuge, E. K., Saprunova, V. B., Severina, I. I., Simonyan, R. A., Skulachev, I. V., Skulachev, M. V., Sumbatyan, N. V., Sviryaeva, I. V., Tashlitsky, V. N., Vassiliev, J. M., Vyssokikh, M. Yu., Yaguzhinsky, L. S., Zamyatnin, A. A., Jr., and Skulachev, V. P. (2008) *Biochemistry (Moscow)*, **73**, 1273-1287.
2. Bakeeva, L. E., Barskov, I. V., Egorov, M. V., Isaev, N. K., Kapelko, V. I., Kazachenko, A. V., Kirpatovsky, V. I., Kozlovsky, S. V., Lakomkin, V. L., Levina, S. B., Pisarenko, O. I., Plotnikov, E. Y., Saprunova, V. B., Serebryakova, L. I., Skulachev, M. V., Stelmashook, E. V., Studneva, I. M., Tskitishvili, O. V., Vasileva, A. K., Victorov, I. V., Zorov, D. B., and Skulachev, V. P. (2008) *Biochemistry (Moscow)*, **73**, 1288-1299.
3. Agapova, L. S., Chernyak, B. V., Domnina, L. V., Dugina, V. B., Efimenko, A. Yu., Fetisova, E. K., Ivanova, O. Yu., Kalinina, N. I., Khromova, N. V., Kopnin, B. P., Kopnin, P. B., Korotetskaya, M. V., Lichinitser, M. R., Lukashev, A. L., Pletjushkina, O. Yu., Popova, E. N., Skulachev, M. V., Shagieva, G. S., Stepanova, E. V., Titova, E. V., Tkachuk, V. A., Vasiliev, J. M., and Skulachev, V. P. (2008) *Biochemistry (Moscow)*, **73**, 1300-1316.
4. Kanda, A., Chen, W., Othman, M., Branham, K. E., Brooks, M., Khanna, R., He, S., Lyons, R., Abecasis, G. R., and Swaroop, A. (2007) *Proc. Natl. Acad. Sci. USA*, **104**, 16227-16232.
5. Justilien, V., Pang, J. J., Renganathan, K., Zhan, X., Crabb, J. W., Kim, S. R., Sparrow, J. R., Hauswirth, W. W., and Lewin, A. S. (2007) *Invest. Ophthalmol. Vis. Sci.*, **48**, 4407-4420.
6. King, A., Gottlieb, E., Brooks, D. G., Murphy, M. P., and Dunaief, J. L. (2004) *Photochem. Photobiol.*, **79**, 470-475.
7. Komeima, K., Rogers, B. S., Lu, L., and Campochiaro, P. A. (2006) *Proc. Natl. Acad. Sci. USA*, **103**, 11300-11305.
8. Komeima, K., Rogers, B. S., Lu, L., and Campochiaro, P. A. (2007) *J. Cell Physiol.*, **213**, 809-815.
9. Ghelli, A., Porcelli, A. M., Zanna, C., Martinuzzi, A., Carelli, V., and Rugolo, M. (2008) *Invest. Ophthalmol. Vis. Sci.*, **49**, 671-676.
10. McKinnon, S. J. (2003) *Front. Biosci.*, **8**, 1140-1156.
11. Tezel, G. (2006) *Prog. Retin. Eye Res.*, **26**, 490-513.
12. Olofsson, E. M., Marklund, S. L., and Behndig, A. (2007) *Free Rad. Biol. Med.*, **42**, 1098-1105.
13. Lassen, N., Bateman, J. B., Estey, T., Kuszak, J. R., Nees, D. W., Piatigorsky, J., Duester, G., Day, B. J., Huang, J., Hines, L. M., and Vasiliou, V. (2007) *J. Biol. Chem.*, **282**, 25668-25676.
14. Brito, B. E., Marcano, J. C., Salazar, E., Cano, M., Baute, L., Bernal, G., and Gonzalez, L. R. (2006) *Ocul. Immunol. Inflamm.*, **14**, 117-124.
15. Pararajasegaram, G., Sevanian, A., and Rao, N. A. (1991) *Ophthalm. Res.*, **23**, 121-127.
16. Kovachich, G. B., and Mishra, O. P. (1980) *J. Neurochem.*, **35**, 1449-1452.
17. Reznick, A., and Packer, L. (1994) *Meth. Enzymol.*, **233**, 357-363.
18. Burke, M. D., Thompson, S., Weaver, R. J., Wolf, C. R., and Mayer, R. T. (1994) *Biochem. Pharmacol.*, **48**, 923-936.
19. Wilden, U., and Kuhn, H. (1982) *Biochemistry*, **21**, 3014-3022.
20. Senin, I. I., Zargarov, A. A., Alekseev, A. M., Gorodovikova, E. N., Lipkin, V. M., and Philippov, P. P. (1995) *FEBS Lett.*, **376**, 87-90.
21. Palczewski, K., Pulvermuller, A., Buczylo, J., and Hofmann, K. P. (1991) *J. Biol. Chem.*, **266**, 18649-18654.
22. Moreno, M. C., Campanelli, J., Sande, P., Saenz, D. A., Sarmiento, M. I. K., and Rosenstein, R. S. (2004) *Free Rad. Biol. Med.*, **37**, 803-813.
23. Grigoryan, E. N., Novikova, Yu. P., Kilina, O. V., and Philippov, P. P. (2007) *Byul. Eksp. Biol. Med.*, **144**, 618-625.

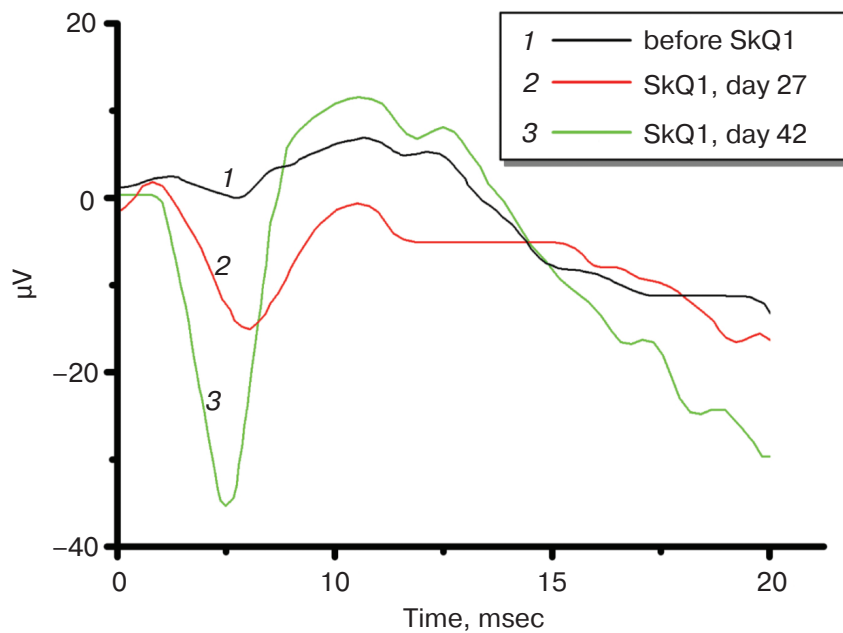
24. Solovyeva, N. A., Morozkova, N. C., and Salganik, R. I. (1975) *Genetika*, **11**, 63-71.
25. Kolosova, N. G., Lebedev, P. A., Aidagulova, S. V., and Morozkova, T. S. (2003) *Byul. Eksp. Biol. Med.*, **136**, 415-419.
26. Sergeeva, S., Bagryanskaya, E., Korbolina, E., and Kolosova, N. (2006) *Exp. Gerontol.*, **41**, 141-150.
27. Kolosova, N. G., Shcheglova, T. V., Sergeeva, S. V., and Loskutova, L. V. (2006) *Neurobiol. Aging*, **27**, 1289-1297.
28. Rajendram, R., Saraswathy, S., and Rao, N. A. (2007) *Br. J. Ophthalmol.*, **91**, 531-537.
29. Machemer, R., and Laqua, H. (1975) *Am. J. Ophthalmol.*, **80**, 1-23.
30. Mueller-Jensen, K., Machemer, R., and Azarnia, R. (1975) *Am. J. Ophthalmol.*, **80**, 530-537.
31. Skulachev, V. P. (2003) in *Topics in Current Genetics*, Vol. 3 (Nystrom, T., and Osiewacz, H. D., eds.) Springer-Verlag, Berlin-Heidelberg, pp. 191-238.
32. Skulachev, V. P., and Longo, V. D. (2005) *Ann. N. Y. Acad. Sci.*, **1057**, 145-164.
33. Zorov, D. B., Filburn, C. R., Klotz, L. O., Zweier, J. L., and Sollott, S. J. (2000) *J. Exp. Med.*, **192**, 1001-1014.
34. Vlachantoni, D., Tulloch, B., Taylor, R. W., Turnbull, D. M., Murphy, M. O., and Wright, A. F. (2006) *Invest. Ophthalmol. Vis. Sci.*, E-5773.



**Fig. 3.** (V. V. Neroev et al.) SkQ1 prevents development of cataract (a) and retinopathies (b) in OXYS rats. c) Electroretinograms of three rats: 1) 3 months, no SkQ1; 2) 24 months, no SkQ1; 3) 24 months, 250 nmol SkQ1/kg per day with food. Flash, 3 cd·sec/m<sup>2</sup>.



**Fig. 7.** (V. V. Neroev et al.) A histological study of sections across the retinas of 24-month-old Wistar (a) and OXYS (b, c) rats. Staining with hematoxylin and eosin. a) Wistar rats: the normal retina structure is well seen, i.e. (1) rods, (2) outer nuclear layer, (3) outer plexiform layer, (4) inner nuclear layer, (5) inner plexiform layer, and (6) ganglionic cell layer. b) OXYS without SkQ1: there is no photoreceptor compartment (rods as well as outer nuclear and plexiform layer are absent). c) OXYS rats obtained SkQ1 with food from age 1.5 month (250 nmol/kg per day). All the layers are present. Typical results are shown. Sixteen eyes (8 rats) were studied in each group. Bar, 50  $\mu$ m.



**Fig. 11.** (V. V. Neroev et al.) Electoretinograms of the left eye of dog Greta (for description of the case, see Supplementary information). Where indicated, one drop of 250 nM SkQ1 was daily applied for 27 or 42 days.